Chemical and Mechanical Skin Resurfacing 154

Gary D. Monheit and Katherine Hrynewycz

Chapter Contents

Preoperative History and Considerations 2633
Chemical Resurfacing Procedures 2636
Mechanical Resurfacing Procedures 2643
Postoperative Care 2646
Complications 2647

Synonyms: ▪ Chemical resurfacing: chemical peeling, chemexfoliation ▪ Mechanical resurfacing: dermabrasion (includes dermasanding) ▪ Jessner's peel: Combes' peel ▪ Baker–Gordon peel: deep phenol peel ▪ Microneedling: percutaneous collagen induction

Key features

- Chemical peeling, dermabrasion, and laser ablation are the three main methods of skin resurfacing
- Chemical and mechanical resurfacing procedures have a long history of safety and efficacy in ameliorating various skin conditions and improving cutaneous photoaging
- Resurfacing procedures represent one part of a comprehensive skin care program that should include photoprotective measures and topical medical and/or cosmeceutical agents
- Each resurfacing procedure injures the skin to a specific depth to promote the regrowth of new skin with improved surface characteristics
- The degree of clinical improvement, the length of the recovery period, and the risk of complications are all proportionate to the depth of tissue injury chosen and skin type
- Selection of suitable patients and proper choice of resurfacing procedure are critical to success
- Both dermabrasion and the "TCA CROSS" technique are methods for treating acne scars
- Microdermabrasion and microneedling are additional approaches for facial rejuvenation
- Prolonged erythema, pigmentary or textural irregularities, infection, delayed healing, and scarring are potential complications of resurfacing
- Resurfacing procedures are a rewarding part of dermatologic practice, both for the patient and for the physician

INTRODUCTION AND HISTORY

Resurfacing procedures to improve the health and appearance of the skin have been utilized by humans for thousands of years. The ancient Egyptians applied various chemicals to the skin and may have even used abrasives like sandpaper to obtain a smoother skin surface[1,2]. Resurfacing methods within the practice of dermatology were initially described over 100 years ago. Early on, chemical cauterants were used primarily for proliferative lesions and skin disorders, with pioneers such as Hebra and Jessner discovering the usefulness of acidic and basic compounds for skin exfoliation. Over the past several decades, the role of chemexfoliation has expanded dramatically to include textural and cosmetic revisions. Our society's increasing emphasis on a youthful image and aesthetic appearance has resulted in an explosion in public demand for commercial skin care products, professional assistance from physicians and non-physicians to assure proper medical and cosmeceutical skin therapy, and procedural intervention. However, the development and application of safe and effective procedures needs to be based upon sound reproducible data.

All ablative resurfacing procedures injure the skin, in a controlled fashion, to a specific depth and thereby promote the growth of new skin with improved surface characteristics. The three fundamental methods used to create this controlled injury are chemical resurfacing (chemical peeling), mechanical resurfacing (motorized dermabrasion or manual dermasanding), and laser resurfacing (see Ch. 137). Chemical resurfacing entails the application of acidic or basic abrasive chemical substances that can destroy selective levels of the epidermis or dermis. Mechanical resurfacing involves smoothing the skin surface with an abrasive surface which physically removes portions of the epidermis and dermis.

In general, skin resurfacing procedures can be classified as superficial, medium-depth, or deep, according to their level of injury (Table 154.1). Skin resurfacing is usually performed only on the face and neck, in part because of the critical aesthetic value of this area. Caution must be exercised in treating the neck, arms, and trunk due to a propensity for complications; only superficial procedures should be performed on the lower one-third of the neck and other non-facial areas. Resurfacing of sites such as the hands and arms has yielded less predictable and less impressive results as well as a higher risk for scarring.

In comparison to the other resurfacing modalities available for skin rejuvenation, chemical resurfacing probably has the longest and most well-documented history[1]. Experimentation with various peeling compounds in the late nineteenth and early twentieth centuries led to sporadic reports in the medical literature describing their use. The initial reports were met with skepticism, but further investigation by both dermatologists and plastic surgeons verified their effectiveness in facial skin rejuvenation and as a treatment for skin disorders. Subsequently, chemical peeling experienced a tremendous growth in popularity and has become an important part of our armamentarium in the management of various cosmetic as well as non-cosmetic skin problems. Currently, chemical peeling is the third most commonly employed cosmetic procedure, after injectable neurotoxins and soft tissue fillers.

Since Kromayer's original report of motorized dermabrasion in 1905, there has been considerable growth not only in chemical resurfacing procedures, but also in mechanical resurfacing. Mechanical resurfacing is most often known as dermabrasion, but it refers to any procedure that involves surgical planing of the skin using an abrasive surface. The use of dermabrasion was originally limited to the treatment of scars, but its role expanded during the latter half of the twentieth century to include a multitude of indications including improvement of elevated skin grafts and rejuvenation of photodamaged skin[2]. Recent adaptations of the traditional techniques of dermabrasion have led to the development of a less invasive procedure, known as microdermabrasion[3]. Dermasanding, which is a manual technique of dermabrasion utilizing abrasive paper, has been in use for centuries, but recently has experienced a resurgence[4,5]. Although overshadowed by ablative and non-ablative laser resurfacing (see Ch. 137), mechanical resurfacing procedures remain a popular option for both patients and physicians.

PREOPERATIVE HISTORY AND CONSIDERATIONS

Indications

The preoperative consultation is important in identifying at-risk patients who are best avoided or who require an extra-cautious approach, as well

Downloaded for Anonymous User (n/a) at Egyptian Knowledge Bank from ClinicalKey.com by Elsevier on March 10, 2024. For personal use only. No other uses without permission. Copyright ©2024. Elsevier Inc. All rights reserved.

CLASSIFICATION OF ABLATIVE SKIN RESURFACING METHODS
Superficial – very light
• Low-potency formulations of glycolic acid or other α-hydroxy acids • 10%–20% TCA (weight-to-volume formulation) • Tretinoin • 20% salicylic acid • Jessner's solution (see Table 154.4)
• Microdermabrasion
Superficial – light
• 50%–70% glycolic acid • Jessner's solution (greater number of coats than for very light peel) • 25%–30% TCA • Solid CO_2 slush • 30% salicylic acid
• Microdermabrasion
Medium-depth
• Jessner's–35% TCA (most popular combination) • 70% glycolic acid – 35% TCA • Solid CO_2–35% TCA (most potent combination) • 40% TCA (not recommended) • 88% phenol (rarely used)
• Conservative manual dermasanding • Erbium:YAG laser resurfacing • Conservative fractional CO_2 laser resurfacing • Ablative fractional erbium:YAG laser resurfacing
Deep
• Unoccluded or occluded Baker–Gordon phenol peel (see Table 154.6) • TCA in concentrations >50% (not recommended)
• Wire-brush or diamond-fraise dermabrasion • Aggressive manual dermasanding • Manual dermasanding or motorized dermabrasion after a medium-depth peel • Aggressive erbium:YAG laser resurfacing • CO_2 laser resurfacing • Combination erbium:YAG/CO_2 laser resurfacing • Ablative fractional CO_2 laser resurfacing

Table 154.1 Classification of ablative skin resurfacing methods. Although this classification represents an oversimplification because the depth of injury actually varies somewhat along a continuum for each different type of resurfacing procedure, it is helpful when discussing the various options with a patient. The lighter shade represents chemical methods and the darker shade mechanical methods. TCA, trichloroacetic acid.

MAJOR INDICATIONS FOR CHEMICAL AND MECHANICAL SKIN RESURFACING
• Actinically damaged skin and rhytides • Scarring • Multiple pre-neoplastic or neoplastic epidermal lesions (e.g. actinic keratoses, lentigines) • Acne, rhinophyma • Pigmentary dyschromias (including tattoos) • Demarcation lines secondary to other resurfacing procedures

Table 154.2 Major indications for chemical and mechanical skin resurfacing.

CONTRAINDICATIONS TO CHEMICAL AND MECHANICAL SKIN RESURFACING
Absolute
• Poor physician–patient relationship • Lack of psychological stability and mental preparedness • Unrealistic expectations • Poor general health and nutritional status • Isotretinoin therapy within the last 6 months*,† • Complete absence of intact pilosebaceous units on the face • Active infection or open wounds such as HSV, excoriations, or open acne cysts
Relative
• Medium-depth or deep resurfacing procedure within the last 3–12 months* • Recent facial surgery involving extensive undermining, such as a rhytidectomy* • History of abnormal scar formation or delayed wound healing • History of therapeutic radiation exposure • History of certain skin diseases (e.g. rosacea, seborrheic dermatitis, atopic dermatitis, psoriasis, vitiligo) or active retinoid dermatitis • Fitzpatrick skin types IV, V and VI*
*These contraindications apply only to medium-depth and deep resurfacing procedures. †General consensus for mechanical dermabrasion and fully ablative laser surgery.

Table 154.3 Contraindications to chemical and mechanical skin resurfacing. HSV, herpes simplex virus.

as in selecting patients who are ideal candidates for intervention. The dermatologist must evaluate the prospective patient and his or her skin condition carefully, in order to determine if a chemical or mechanical resurfacing procedure is indicated. When resurfacing is deemed appropriate, selection of the proper procedure for each patient is critical to assure that the desired results are achieved in a safe and effective manner. The depth of the injury that must be created by resurfacing to achieve significant improvement is related to the degree of skin surface irregularities and their depth. There are six major indications for resurfacing (Table 154.2).

Pre-neoplastic or neoplastic skin lesions can certainly be removed or improved with resurfacing procedures. Those originating in the epidermis, such as actinic keratoses, lentigines, and seborrheic keratoses are more amenable to treatment than those with a dermal extension or origin. Although some dermatologic conditions may be aggravated by resurfacing, acne and pigmentary dyschromias such as melasma respond favorably to superficial chemical peeling or microdermabrasion, especially when accompanied by appropriate cosmeceutical products and sunscreens. Another indication for chemical and mechanical skin resurfacing is to blend the effects of other procedures, e.g. ablative laser resurfacing of periocular or perioral rhytides, by preventing or eliminating lines of demarcation.

Photoaging is probably the single condition for which skin resurfacing procedures are most often performed. For patients with photoaging, the Glogau system (see Ch. 152) is helpful in deciding upon the most appropriate skin rejuvenation program. It classifies patients into one of four groups based on degree of severity. Patients in category I are often young with minimal to mild photoaging and are best managed with superficial chemical peels or microdermabrasion in conjunction with topical medications or cosmeceuticals (e.g. retinoids, glycolic acids, exfoliants, antioxidants, vitamin C, vitamin E). Patients in category II would likely benefit from a medium-depth chemical peel as well as long-term medical therapy to include a retinoid and/or an α-hydroxy acid (AHA). Individuals in category III typically need prolonged medical treatment in conjunction with one of the following: a medium-depth chemical peel (with or without dermasanding), a deep chemical peel, dermabrasion, or laser resurfacing. For patients with category IV photoaging, interventions utilized for category III individuals are also recommended, but the addition of an invasive surgical operation such as a rhytidectomy or blepharoplasty is often required to achieve the desired results. Nowadays, reconstruction of facial form and correction of deep furrows with injectable neurotoxins and soft tissue fillers is such that resurfacing techniques represent a final stage in the combination approach to facial rejuvenation (see Chs. 158 and 159).

Contraindications and Patient Selection

When evaluating a patient for chemical or mechanical resurfacing, a careful history and physical examination are important to assess the skin problems which prompted his or her presentation and to identify any factors that may contribute to intraoperative or postoperative difficulties (Table 154.3). It is best not to inject soft tissue fillers on the same day as a chemical peel. The patient should also be asked about prior resurfacing procedures, rhytidectomy (facelift), or oral isotretinoin therapy within the last six months, as these can increase the risk of complications following medium-depth and deep resurfacing[6,7].

Downloaded for Anonymous User (n/a) at Egyptian Knowledge Bank from ClinicalKey.com by Elsevier on March 10, 2024. For personal use only. No other uses without permission. Copyright ©2024. Elsevier Inc. All rights reserved.

Although some clinicians no longer require a six-month waiting period post isotretinoin administration, the authors still adhere to this recommendation. Any history of abnormal scar formation or therapeutic radiation exposure warrants extreme caution when considering a patient for skin resurfacing. Individuals with prior radiation exposure should be examined closely for the presence of intact facial hair to ensure that there are enough pilosebaceous units to promote re-epithelialization[8].

Another important element of the patient's history is the presence or absence of a prior herpes simplex viral (HSV) infection. Because recurrence of oral HSV can be triggered by a resurfacing procedure, especially in the perioral and periorbital regions, antiviral therapy (e.g. valacyclovir) is administered prophylactically (see below). Risk factors for HIV infection or viral hepatitis should be identified, and in the authors' opinion, routine laboratory screening is recommended in individuals undergoing dermabrasion with a powered engine. A history of abnormal wound healing from trauma or previous procedures, such as hypertrophic scarring or dyschromia, may be a contraindication to peeling or dermabrasion. The general health and nutritional status of the patient is also an important consideration, especially for medium-depth and deep resurfacing procedures, to ensure timely and complete healing.

Patients with certain cutaneous disorders, such as rosacea, seborrheic dermatitis, atopic dermatitis, psoriasis or vitiligo, may be at increased risk for postoperative complications, including disease exacerbation, prolonged erythema, contact dermatitis, or even delayed healing. In particular, individuals with rosacea have vasomotor instability and may develop an exaggerated inflammatory response to the resurfacing procedure. Caution should also be exercised for patients with autoimmune connective tissue diseases, including cutaneous lupus and systemic sclerosis, as the trauma of chemical peeling may exacerbate the disease. Evaluation of the patient's Fitzpatrick skin type (see Ch. 0) is helpful in predicting the chance of postoperative hyper- or hypopigmentation. Individuals with Fitzpatrick skin types I or II are at low risk for dyspigmentation after medium-depth or deep resurfacing, whereas those with types III through VI are at greater risk for these complications[9].

The patient should understand that chemical and mechanical resurfacing procedures cannot reliably reduce pore size, and their ability to improve lax skin or deeper wrinkles and scars is limited and depends upon the type of intervention being performed. While dermabrasion may sometimes eliminate telangiectasias, chemical peels cannot accomplish this and can even unmask them by removing the pigmentary irregularities. The patient must fully understand the potential benefits, limitations and risks of the procedure, and an informed consent must be signed.

A test spot (e.g. along the lateral hair line) may be useful in some patients to assess their suitability for resurfacing and may be particularly helpful when there is a great deal of concern about the chances of postoperative pigmentary dyschromias[10]; test spots are definitely recommended for individuals with skin types III–VI. Of note, while a favorable test spot result does not guarantee a positive outcome following full-face resurfacing, an unfavorable test spot result is useful in identifying high-risk patients. The latter include those at risk for postinflammatory hyperpigmentation, spotting, irregular coloration, hypopigmentation, or poor or delayed healing. If the dermatologist feels any uncertainty about the patient's suitability or the likelihood of a favorable result, the procedure should not be performed.

Pre-treatment photographs – full-face frontal, lateral and oblique views as well as problem areas – are essential for documenting baseline appearance. They also allow for accurate assessment of postoperative improvement.

Preoperative and Intraoperative Preparations

Another purpose of the preoperative consultation is to ensure that the patient is adequately prepared for the procedure. Almost every patient desiring facial rejuvenation for cutaneous photoaging would benefit from botulinum toxin injections to alleviate dynamic wrinkles (see Ch. 159). These injections appear to enhance the results of deeper resurfacing procedures by immobilizing the muscles implicated in the development of dynamic rhytides during the critical time of postoperative collagen remodeling. In patients with photoaging, it is recommended that botulinum toxin injections be administered as an adjunctive therapy at least 3 days prior to medium-depth or deep chemical peels, dermabrasion, or laser resurfacing.

Due to the significant morbidity associated with herpetic infections during the healing period, patients who undergo medium-depth or deep resurfacing (see Table 154.1) should be treated prophylactically with an antiviral agent, regardless of whether there is a history of HSV infections[11]. These drugs are not routinely given to patients having a superficial chemical peel or microdermabrasion, because the injury is generally not sufficient to activate the virus. However, preventive therapy may be considered in conjunction with superficial resurfacing in patients with a strong personal history of recurrent HSV infections. Recommended prophylaxis consists of acyclovir 400 mg three times daily, valacyclovir 500 mg twice daily or famciclovir 250 mg twice daily, beginning on the day of the procedure. It is advisable to administer the drug for at least 10 to 14 days thereafter[12]. The reason for such a long duration of therapy is that viral replication is possible only in intact epidermal cells, making clinical infection unlikely during the first few days postoperatively. The risk of an eruption increases dramatically with the onset of re-epithelialization and remains high until healing is complete.

It is important that the patient adhere to a strict skin care regimen during the immediate preoperative and postoperative periods to achieve optimal results. The authors treat patients with topical tretinoin on a nightly basis prior to the procedure. Retinoids increase epidermal proliferation and presumably lead to more rapid re-epithelialization after the chemical peel. Because of the tendency for retinoids to cause irritation within 1 to 2 weeks of starting therapy (i.e. retinoid dermatitis), a retinoid formulation with lower irritation potential should be used in patients with sensitive skin. The retinoid should be discontinued one week prior to the chemical peel. In patients with active retinoid dermatitis, resurfacing should be delayed because this condition may lead to a prolongation in postoperative erythema. Decreasing the frequency of application or switching to a less irritating retinoid will allow the inflammation to subside, so that the procedure can be performed[13].

All-*trans*-retinoic acid, or tretinoin, has been classified as a superficial chemical peeling agent, but it is best considered as an integral component of a complete skin rejuvenation program. With chronic use, this drug has been shown to improve actinically damaged skin both clinically and histologically[14]. The use of tretinoin prior to chemical peeling, dermabrasion, or laser resurfacing speeds epidermal healing and enhances the effects of the procedure[13,14]. For chemical peels in particular, use of preoperative topical tretinoin to reduce areas of hyperkeratosis and decrease the thickness of the stratum corneum allows for greater penetration of the peel solution, resulting in a more homogeneous peel and a deeper peel. Use of tretinoin is restricted, however, during the postoperative healing period, until there is diminished inflammatory erythema and complete re-epithelialization with a fully mature epidermis.

Hydroquinone inhibits the enzyme tyrosinase and can reduce the production of epidermal melanin during the healing phase. Patients with skin type III or higher may benefit from twice-daily application of 2% to 4% topical hydroquinone during the preoperative and postoperative (post-healing) periods – even if there is no history of pigmentary abnormalities[9]. It is also necessary to use hydroquinone in patients of any skin type when peeling is done to treat pigmentary dyschromias such as melasma or postinflammatory hyperpigmentation[9]. While a Wood's lamp was used in the past to localize melanin pigment to either the epidermis or dermis (i.e. epidermal versus dermal melasma), histopathologic studies and confocal microscopy have shown that there is often a mixture of the two forms in an individual patient. Nonetheless, in both melasma and postinflammatory hyperpigmentation, increased melanin within the epidermis responds better to superficial peels than does dermal pigment. The use of non-inflammatory peeling agents, e.g. salicylic acid, is preferred for disorders such as melasma as there is less tendency for postinflammatory hyperpigmentation (Fig. 154.1).

All patients undergoing any type of skin resurfacing procedure must adhere to strict photoprotective measures during the postoperative period. This issue is critical in patients whose Fitzpatrick skin type is III or higher, in patients with pigmentary abnormalities, in patients taking exogenous estrogens, and in all patients having medium-depth or deep resurfacing. Specific methods to minimize sun exposure and proper use of sun blocks should be discussed. Patients are also counseled to avoid tobacco use, as smoking in the postoperative period may interfere with the healing process, thereby limiting the effectiveness of the resurfacing and increasing the risk of poor wound healing.

Downloaded for Anonymous User (n/a) at Egyptian Knowledge Bank from ClinicalKey.com by Elsevier on March 10, 2024. For personal use only. No other uses without permission. Copyright ©2024. Elsevier Inc. All rights reserved.

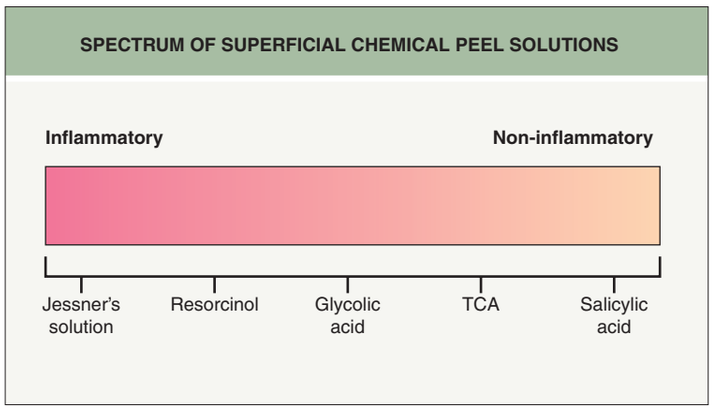

Fig. 154.1 Spectrum of superficial chemical peel solutions. Inflammatory chemical peel solutions are used primarily for photoaging, while non-inflammatory chemical peel solutions are best for Fitzpatrick skin types III–VI, melasma, and postinflammatory hyperpigmentation. TCA, trichloroacetic acid.

The need for intraoperative sedation and analgesia is also discussed with the patient preoperatively, so that plans are made accordingly. Superficial resurfacing procedures usually require only "talkesthesia," a technique that is extremely helpful in awake patients undergoing a procedure, i.e. talking calmly to the patient with encouragement during the procedure. Medium-depth chemical or mechanical resurfacing usually requires a limited degree of perioperative sedation and analgesia, which may include the application of topical amide anesthetics and regional blocks of the supraorbital, infraorbital, and mental nerves (see Ch. 143), as well as oral diazepam, intramuscular meperidine hydrochloride, and/or intramuscular hydroxyzine hydrochloride. Although deep resurfacing procedures can be accomplished entirely with nerve blockade, local injections of lidocaine, and mild sedatives, some patients require intravenous or general (endotracheal tube) anesthesia. Application of the tumescent technique (see Ch. 156) to resurfacing has allowed many patients to undergo deep resurfacing procedures without the additional risks of intravenous or general anesthesia[15]. The patient's inherent pain tolerance, level of anxiety, concomitant medical conditions, and willingness to pay the extra costs of heavier sedation are important topics to discuss during the preoperative consultation that is used to plan for appropriate anesthesia.

Preoperatively, the patient must be given specific instructions to follow, both for the day of the procedure and for postoperative care. These should be carefully reviewed verbally prior to the procedure, with the same instructions provided in written form. On the day of the procedure, the patient washes his or her face with a gentle cleanser and preferably avoids the application of any cosmetics. Individuals undergoing procedures requiring minimal or no sedation are encouraged to eat a light breakfast, but patients receiving deeper anesthesia should have nothing by mouth except for their usual medications. Particularly for medium-depth and deep resurfacing procedures, the dermatologist should meet with the patient and his or her family preoperatively to re-establish rapport, answer last-minute questions, discuss perioperative and postoperative expectations and instructions, and assure compliance with antiviral prophylaxis as needed.

CHEMICAL RESURFACING PROCEDURES

Although there is currently a wide variety of resurfacing procedures available for facial rejuvenation, chemical peeling remains a popular choice for both patient and physician. In comparison to some of the newer options, chemical peels have a longstanding safety and efficacy record, are performed with ease, are low in cost, and have a predictable and relatively quick recovery time. Various acidic and basic compounds are used to produce a controlled skin injury and are classified as superficial, medium-depth, and deep peeling agents, according to their level of penetration, destruction, and inflammation (see Table 154.1). In general, superficial peels cause epidermal injury and occasionally extend into the papillary dermis, medium-depth peels cause injury through the papillary dermis to the upper reticular dermis, and deep peels cause injury down to the mid-reticular dermis[16].

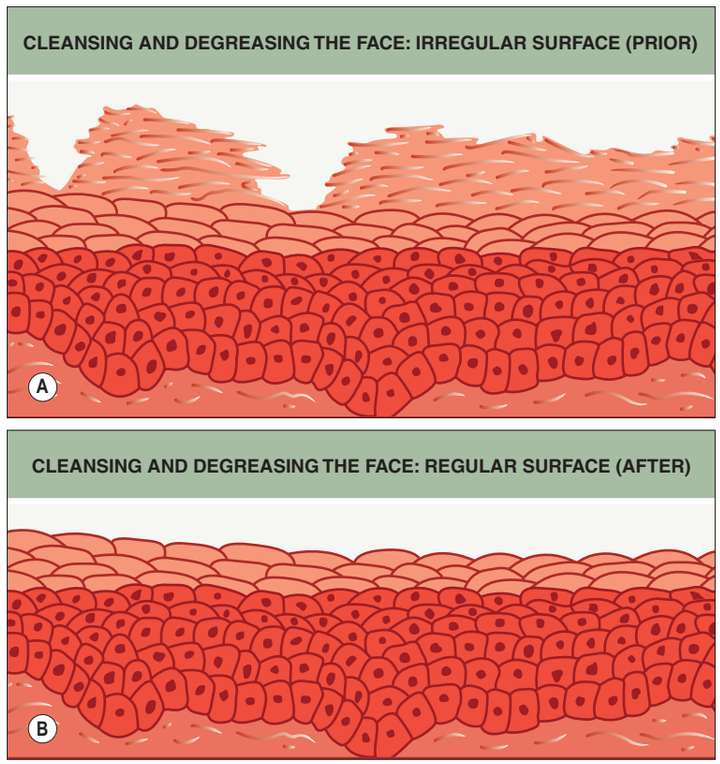

Fig. 154.2 Cleansing and degreasing the face. A Irregular surface (prior). **B** Clean, regular surface (after).

Prior to the application of peeling solutions, the skin surface must be vigorously cleansed to remove residual oils, debris, and excess stratum corneum. The authors use gauze pads with an effective detergent cleanser, followed by rinsing with water and drying. Because of the defatting and degreasing properties of acetone, gauze pads moistened with an acetone preparation are then used to cleanse the skin even further. Finally, the cleansed skin is palpated immediately prior to peeling to check for the presence of residual oil and if any is felt, the process is repeated. *The importance of cleansing prior to the peeling procedure cannot be overemphasized*. A thorough and evenly distributed cleansing and degreasing of the face assures uniform penetration of the peeling solution and leads to an even result without skipping areas (Fig. 154.2).

The effect of a chemical peel is dependent upon the agent used, its concentration, and the techniques employed before and during its application. Each wounding agent used in peels has unique chemical properties and causes a specific pattern of injury to the skin[15–20]. It is important for the physician using these solutions to be familiar with their cutaneous effects and proper methods of application, to assure correct depth of injury. The marketplace has been flooded with numerous proprietary formulations of peeling agents with each product claiming unique advantages. These products are often expensive and have not been shown to be safer or more effective than the conventional solutions. Their advantage rests in the prepackaging of materials and ease for the physician. The following discussion on superficial, medium-depth, and deep peeling will therefore focus on the specific chemical agents that are responsible for producing the various patterns of injury rather than proprietary products.

Superficial Chemical Peeling

Superficial chemical peels are indicated in the management of acne and its postinflammatory sequelae, mild photoaging (Glogau I and II), and epidermal lesions such as lentigines and keratoses, as well as melasma and other pigmentary dyschromias[21]. A series of peels is usually necessary to obtain optimal results[22]. The frequency of peels and degree of exposure to the peeling agent may be increased gradually as necessary. Results are enhanced by medical or cosmeceutical therapy, including a retinoid, antioxidants and, if necessary, a bleaching agent. All superficial chemical peels share the advantages

Downloaded for Anonymous User (n/a) at Egyptian Knowledge Bank from ClinicalKey.com by Elsevier on March 10, 2024. For personal use only. No other uses without permission. Copyright ©2024. Elsevier Inc. All rights reserved.

JESSNER'S SOLUTION (COMBES' FORMULA)	
Resorcinol	14 g
Salicylic acid	14 g
85% lactic acid	14 g
95% ethanol (q.s.ad)	100 ml

Table 154.4 Jessner's solution (Combes' formula). q.s.ad, a sufficient quantity up to.

of only mild stinging and burning during application as well as minimal time (a few days) needed for recovery.

Superficial chemical peels are divided into two varieties – very light and light (see Table 154.1). With *very light* peels, the injury is usually limited to the stratum corneum and only creates exfoliation; however, the injury may extend into the stratum granulosum. The agents used for these peels include low-potency formulations of glycolic acid, 10%–20% trichloroacetic acid (TCA), tretinoin, 20% salicylic acid, and Jessner's solution (Table 154.4)[23–25]. *Light* peels injure the entire epidermis down to the basal layer, stimulating the regeneration of a fresh new epithelium. Agents used for light peels include 50%–70% glycolic acid, 25%–30% TCA, Jessner's solution (greater number of coats than for very light peels), 30% salicylic acid, and solid CO_2 slush[23,24]. During the application of superficial peeling agents, there may be mild stinging followed by a level I frosting, defined as the appearance of erythema and streaky whitening on the surface (Fig. 154.3).

Alpha-hydroxy acids (AHAs) are naturally found in foods and have been used widely in skin rejuvenation regimens since the early 1990s. The depth of injury is determined by the specific AHA used, its pH, the concentration of free acid, the volume applied to the skin, and the duration of contact. In low concentrations, AHAs have been shown to decrease the cohesion of corneocytes at the junction of the stratum corneum and the stratum granulosum[26]. Higher concentrations are associated with complete epidermolysis. With chronic use of AHA-containing products on a daily basis, there is an increase in skin thickness, acid glycosaminoglycans (mucopolysaccharides), and the density of collagen, as well as an improvement in elastic fiber quality[19]. The most popular of the AHAs, **glycolic acid**, is available in a variety of over-the-counter preparations and can be purchased by physicians in buffered as well as unbuffered concentrations as high as 70% for chemical peels. Twice monthly or every other week applications of 40%–70% glycolic acid (with cotton swabs, a sable brush, or 2×2-inch gauze pads) have been used most often for acne, mild photoaging, and melasma[27]. The time of application is critical for glycolic acid, as it must be rinsed off with water or neutralized with 5% sodium bicarbonate after 2 to 4 minutes. It is the only peeling agent that is time-dependent, requiring neutralization to end its action.

Application of 10%–20% **TCA** with either a saturated gauze pad or sable brush produces erythema and a very light frost within 15 to 45 seconds. The depth of penetration of the peeling solution is related to the number of coats applied. Epidermal protein denaturation results in exfoliation without vesiculation. Concentrations of TCA up to 25% can be used alone as a superficial peeling agent but may create an injury and inflammation that extends partially into the upper dermis. **Jessner's solution** is a combination of keratolytic ingredients that has been used for over 100 years in the treatment of inflammatory and comedonal acne as well as hyperkeratotic skin disorders (see Table 154.4). Jessner's solution has intense keratolytic activity, initially causing loss of corneocyte cohesion within the stratum corneum and subsequently creating intercellular and intracellular edema within the upper epidermis if application is continued[28]. The mode of application for the Jessner's peel is similar to that of the 10%–20% TCA peel. The clinical endpoint of treatment is erythema with blotchy frosting (when used prior to application of TCA in medium-depth peels) or a more uniform frosting (when used alone for superficial peels). While Jessner's peel can be used in extrafacial sites, care must be taken to restrict the total amount of peel solution, as salicylic acid is absorbed systemically.

Salicylic acid, also referred to as a β-hydroxy acid, is one of the ingredients in Jessner's solution. It can be used alone for superficial chemical peeling and is a preferred therapy for comedonal acne and inflammatory rosacea as it is lipophilic and concentrates within the pilosebaceous apparatus (Fig. 154.4)[25]. Salicylic acid is quite effective

Fig. 154.3 Levels of frosting. A Level I frosting as found with light chemical peeling: erythema with streaky frosting. **B** Level II frosting: erythema with diffuse white frosting. **C** Level III frosting: solid white enamel frosting.

as an adjunctive therapy for both open and closed comedones and for resolving post-acne erythema. As noted previously, salicylic acid produces less inflammation than other superficial peeling agents (see Fig. 154.1) and therefore is associated with a lower risk of postinflammatory hyperpigmentation. Salicylic acid is the preferred peeling agent for removing the excess pigmentation in melasma and postinflammatory hyperpigmentation. It is safer and more effective in reducing epidermal pigment, especially when combined with a bleaching agent (e.g. hydroquinone) and sunscreens.

Downloaded for Anonymous User (n/a) at Egyptian Knowledge Bank from ClinicalKey.com by Elsevier on March 10, 2024. For personal use only. No other uses without permission. Copyright ©2024. Elsevier Inc. All rights reserved.

Fig. 154.4 Salicylic acid peels. These peels are effective for the treatment of acne, including comedones. Repetitive peels over 6 weeks combined with medical acne treatment will hasten resolution of the condition. Note the perifollicular frosting seen with salicylic acid, a lipophilic chemical.

Prior to the initial treatment, the patient must understand that the net effect of repetitive superficial chemical peels never approaches the beneficial effect obtained with a single medium-depth or deep peel. The improvements in cutaneous photoaging following superficial peels are usually subtle because there is little to no effect on the dermis. These peels thus cannot produce an appreciable effect on textural changes such as deep wrinkles and furrows, which originate within the dermis. Nonetheless, their ease of use and minimal downtime makes these "lunchtime" peels rewarding for patients with realistic expectations and are a favorite of busy patients. Superficial peels are best employed in combination with cosmeceutical agents and other minimal- to no-downtime procedures such as botulinum toxin A injections, microneedling, and intense pulsed light treatments. Desired and expected results include a "brightened" skin appearance with a more uniform color and texture.

Fig. 154.5 Jessner's–35% trichloroacetic acid (TCA) chemical peel. A Before treatment. **B** 3 days after treatment. **C** 6 days after treatment. **D** 2 months after treatment.

Medium-Depth Chemical Peeling

Medium-depth chemical peels consist of controlled damage through the epidermis and into the papillary dermis, with variable extension to the upper reticular dermis. Both medium-depth and deep chemical peels produce epidermal necrosis plus papillary dermal edema and homogenization with a sparse lymphocytic infiltrate within the first several days[15]. Postoperatively, over a period of 3 months, there is increased collagen production with expansion of the papillary dermis and the development of a mid-dermal band of thicker collagen fibers. These changes correlate with the clinical improvement in texture, fine lines, and color observed over time (Fig. 154.5).

For many years, 40%–50% TCA was the prototypical medium-depth peeling agent because of its ability to ameliorate fine wrinkles, actinic changes, and "pre-neoplasias". TCA as a single agent for medium-depth peeling has fallen out of favor because of the high risk of complications, especially scarring and pigmentary alterations, when used in strengths approaching 50% and higher[29]. Today, most medium-depth chemical peels are performed utilizing 35% TCA in combination with Jessner's solution, 70% glycolic acid, or solid CO_2 as the "priming" agent. These combination peels have been found to be as effective as 50% TCA alone, but safer with fewer risks[30]. The level of penetration is better controlled with these combination peels, thereby preventing the "hot spots" seen with higher concentrations of TCA that can produce dyschromia and scarring.

Brody and Hailey[31] developed the use of solid CO_2 to freeze the skin prior to the application of 35% TCA. This causes epidermal necrosis and significant dermal edema, thereby allowing deeper penetration of the TCA in selected areas. This technique is particularly useful for effacing the edges of mild acne scars and destroying thicker epidermal growths. Monheit[28] then described a combination medium-depth peel in which Jessner's solution is first applied, followed by 35% TCA, with comparable clinical results. Similarly, Coleman and Futrell[32] have demonstrated the usefulness of 70% glycolic acid prior to the application of 35% TCA for medium-depth peeling. Jessner's solution and glycolic acid both appear to effectively weaken the epidermal barrier and allow deeper, more uniform and more controlled penetration of 35% TCA.

Current indications for medium-depth chemical peeling include Glogau group II cutaneous photoaging, epidermal lesions such as actinic keratoses, pigmentary dyschromias, and mild acne scarring, as well as blending of the effects of deeper resurfacing procedures. The most popular of the medium-depth peels for facial rejuvenation is the Jessner's–35% TCA peel. This peel has been widely accepted because of its broad range of uses, the large number of individuals in whom it is indicated, its ease of modification according to the patient or situation, and its excellent safety profile.

The Jessner's–35% TCA peel is particularly useful for the improvement of mild to moderate photoaging (Fig. 154.6). It freshens sallow, atrophic skin and softens fine rhytides, with minimal risk of textural or pigmentary complications. Collagen remodeling occurs for as long as 3 to 4 months postoperatively during which time there is continued improvement in texture and rhytides. Deep furrows, however, are not eliminated with this peel and there is no significant skin retraction as is seen with ablative fractional laser resurfacing or deep chemical peels. When used in conjunction with a retinoid, bleaching agent, and sunscreens, a single Jessner's–35% TCA peel lessens pigmentary dyschromias and lentigines more effectively than repetitive superficial peels. Epidermal growths such as actinic keratoses

Downloaded for Anonymous User (n/a) at Egyptian Knowledge Bank from ClinicalKey.com by Elsevier on March 10, 2024. For personal use only. No other uses without permission. Copyright ©2024. Elsevier Inc. All rights reserved.

Fig. 154.6 Medium-depth chemical peel used to treat moderate photoaging of the skin. A Preoperative, demonstrating actinic keratoses plus aging textural changes. **B** Application of 35% trichloroacetic acid (TCA) directly after Jessner's solution. **C** White enamel frosting (level III) from 35% TCA. **D** Desquamation and inflammation 4 days after peel. **E** Final results 6 months later.

also respond well to this peel. In fact, the Jessner's–35% TCA peel has been found to be as effective as topical 5-fluorouracil in removing both grossly visible and clinically undetectable actinic keratoses while having the added advantages of lower morbidity and greater improvement in associated photoaging[33,34].

Another indication for the Jessner's–35% TCA peel is to blend the effects of other resurfacing procedures with the surrounding skin[35]. Patients who have undergone ablative fractional CO_2 laser resurfacing, deep chemical peeling or dermabrasion to a localized area such as the periorbital or perioral region often develop a sharp line of demarcation between the treated and untreated skin. The treated skin may appear hypopigmented (also known as pseudohypopigmentation) in comparison to the untreated photodamaged skin. These irregularities are often conspicuous and are troubling to the patient. A Jessner's–35% TCA peel performed on the adjacent untreated skin helps to blend the treated area into its surroundings. For example, a patient with advanced photoaging in the periorbital region and moderate photoaging on the remaining face may desire fractional CO_2 laser resurfacing only around the eyes. In this patient, medium-depth chemical peeling of the areas not treated with the laser would improve the photoaging in these regions and avoid a line of demarcation[36] (Fig. 154.7). Similarly, a patient with acne or surgical scars having spot or regional dermabrasion or ablative fractional laser resurfacing to a facial cosmetic unit would benefit from a Jessner's–35% TCA peel to the remainder of that cosmetic unit or to the rest of the face. It is important to note that when used in combination with other resurfacing procedures such as laser ablation or dermabrasion, the peel should be performed first, in order to avoid accidental application of the peeling agent onto previously abraded or laser-treated areas, which may lead to scarring (Fig. 154.8).

Using either cotton-tipped applicators or gauze pads, a single, even coat of Jessner's solution is applied first to the forehead, then the cheeks, nose and chin, and, lastly, the eyelids. Proper application of Jessner's solution causes minimal discomfort and creates a faint frost within a background of mild erythema (Fig. 154.9A)[37]. After waiting 1 to 2 minutes for the Jessner's solution to completely dry, 35% TCA is applied evenly with one to four cotton-tipped applicators (Fig. 154.9B). The ultimate effectiveness of this peel is directly dependent upon the depth of penetration of the peeling solutions, and this depth is a function of the adequacy of degreasing and the amount of both solutions applied. The use of cotton swabs, particularly for the application of TCA, is advantageous because it allows the surgeon to quantitatively vary the amount of solution applied according to the patient's specific needs. *The amount of TCA delivered to the skin surface is determined by the number of applicators used, their degree of saturation, the amount of pressure applied to the skin surface, and the duration of their contact with the skin*. Four moist cotton-tipped applicators are applied in broad strokes over the forehead and on the medial cheeks. Two mildly soaked cotton-tipped applicators can be used across the lips and chin, and one damp cotton-tipped applicator on the eyelids (Fig. 154.9C). In addition to location, these parameters are varied based on skin thickness and degree of photodamage.

When applying TCA, anatomic areas of the face are peeled sequentially from the forehead to the temple to the cheeks and finally to the lips and eyelids. Careful feathering of the solution into the hairline and around the rim of the jaw and brow conceals the demarcation line between peeled and non-peeled skin. Areas of wrinkled skin are stretched taut with the help of an assistant, to allow even application of the solution into the folds and troughs. This technique is particularly

Downloaded for Anonymous User (n/a) at Egyptian Knowledge Bank from ClinicalKey.com by Elsevier on March 10, 2024. For personal use only. No other uses without permission. Copyright ©2024. Elsevier Inc. All rights reserved.

helpful on the skin of the upper and lower lips. For perioral rhytides, TCA is applied with the wooden portion of a cotton-tipped applicator and extended onto the vermilion border (Fig. 154.9D).

Eyelid skin must be treated delicately and carefully to avoid over-application to this thinner skin and to prevent exposure of the eyes to the TCA solution. The patient should be positioned with the head elevated at 30°. Excess peel solution on the cotton tip should be squeezed out so that the applicator is semi-dry. With the eyes closed, a single applicator is rolled gently from the periorbital skin onto the upper eyelid skin without going below the superior aspect of the tarsal plate. Another semi-dry applicator is then rolled onto the lower eyelid skin within 2 to 3 mm of the lid margin while the patient is looking superiorly. Excess peel solution should never be left on the lids because it can roll into the eyes. Any tears should be immediately dried with a cotton-tipped applicator because they may pull the solution into the eye by capillary action (see Fig. 154.9C). Tears can also travel down the cheek and carry TCA onto the neck, resulting in a linear streak.

Fig. 154.7 Combination of medium-depth peel of the face plus CO_2 laser ablative resurfacing of the periorbital region. A Before treatment. **B** After treatment.

The white frost from TCA application appears on the treated area within 30 seconds to 2 minutes. This response is representative of keratocoagulation and indicates that the TCA's physiologic reaction is complete. The Jessner's–35% TCA combination takes longer to frost than phenol preparations, but a shorter period of time than the superficial peeling agents. The desired endpoint for medium-depth peeling is level II to level III frosting. Level II frosting is defined as uniform white-coated frosting with a background of erythema (see Fig. 154.3B). Level III frosting, which is associated with penetration to the reticular dermis, is a solid white enamel frosting with no background of erythema (see Fig. 154.3C). A deeper level III frosting should be restricted solely to areas of thick skin and heavy actinic damage. Most medium-depth chemical peels achieve a level II frosting and this is especially important over the eyelids and areas of sensitive skin. Areas with a greater tendency to form scars, such as the zygomatic arch and the bony prominences of the jawline and chin, should receive no greater than level II frosting.

Before re-treating an area, the surgeon should wait at least 3 to 4 minutes after the application of TCA, to ensure that frosting has reached its peak. Each cosmetic unit is then assessed, and areas of incomplete or uneven frosting are carefully re-treated with a thin application of TCA. Additional applications of TCA increase the depth of penetration as well as the risk of complications, so one should apply more solution only to the underfrosted areas. In other words, do not apply 35% TCA to fully frosted areas as this may cause inflammation beyond the level expected and potentially lead to scarring. Thicker keratoses do not frost as well as the surrounding skin, so vigorous rubbing of the lesion may be needed for adequate TCA penetration. If necessary, thicker epidermal lesions may be treated with liquid nitrogen cryotherapy for several seconds prior to the application of TCA. As will be discussed later, mechanical abrasion can also be performed in selected areas at the completion of the Jessner's–35% TCA chemical peel, to enhance the results.

Although there is an immediate burning sensation as the peel solution is applied, the discomfort begins to subside as frosting occurs and resolves fully by the time of discharge. If necessary, a topical amide anesthetic can be applied under occlusion prior to a medium-depth peel for pain relief[38]. Cool saline compresses offer symptomatic relief at the conclusion of the peel. Unlike the compresses utilized in glycolic acid peels, the saline following a TCA peel simply provides relief and does not "neutralize" the acid.

TCA CROSS

The "TCA CROSS" (TCA *c*hemical *r*econstruction *o*f *s*kin *s*cars) technique is an innovative approach to deep ice-pick and fibrotic acne scars (Fig. 154.10A). Rather than a peel or method of exfoliation, it is

Fig. 154.8 Combination procedure utilizing perioral–periorbital CO_2 laser resurfacing with Jessner's–35% trichloroacetic acid (TCA) peel to the remainder of the face. The peel will blend the color and texture of the laser-treated areas. **A** Preoperative: the eyelids and lips need deeper resurfacing than do the cheeks, which require only medium-depth injury. **B** Four days postoperative: note difference in the rate of healing between laser- and peel-treated areas. **C** One year postoperative.

Downloaded for Anonymous User (n/a) at Egyptian Knowledge Bank from ClinicalKey.com by Elsevier on March 10, 2024. For personal use only. No other uses without permission. Copyright ©2024. Elsevier Inc. All rights reserved.

Fig. 154.9 Technical aspects of the Jessner's–35% trichloroacetic acid (TCA) peel. A Appearance of level I frosting after application of Jessner's solution – erythema with blotchy frosting. **B** 35% TCA applied, after Jessner's solution dries, with an even application using cotton-tipped applicators (one to four). A level III or white enamel frosting is obtained. **C** Eyelids are treated with one cotton-tipped applicator moistened with 35% TCA. A dry applicator is used to absorb tears during eyelid peeling. **D** Lip rhytides are peeled with saturated cotton-tipped applicators. The wooden shaft is used to rub peel solution further into the lip rhytides.

Fig. 154.10 "TCA CROSS" technique used as a destructive method for ice-pick scars. A Preoperative with ice-pick scars of the nose and cheek. **B** Frosting limited to just the ice-pick scars. **C** Postoperative.

the use of 90% TCA as a full-thickness destructive tool. When applied to an ice-pick scar, it destroys the epidermis and its deep dermal tunnel, creating a full-thickness skin wound which will heal with the formation of new collagen, thus filling the depressed scar. This method offers a simpler approach to these full-thickness depressions in which the alternatives are surgical: punch grafts, excision, and scar revision. The procedure is performed independently of other resurfacing procedures such as peeling, laser resurfacing or dermabrasion.

After the face is cleansed and degreased with acetone (see above), the ice-pick and depressed fibrotic scars to be treated are outlined with a skin marker and photographed. This serves as a guide for further treatment sessions. The 90% TCA is applied to the interior of the ice-pick scar with a toothpick, being careful not to drip the acid onto normal skin as this could lead to additional scarring. Of note, this is a full-thickness destruction of skin and not a peel, so the TCA should be applied *only* to the interior of the scar itself[39]. Each of the scars is treated until a brilliant white frosting appears (Fig. 154.10B). A topical antibiotic is then placed on each treated site. The procedure is performed with no anesthesia or sedation, as it only produces a brief stinging equivalent to the sensation of cryosurgery.

Healing occurs over the next 2 to 3 weeks, with granulation tissue, fibroplasia, and remodeling of new collagen, which will elevate and soften the depressed scars (Fig. 154.10C). The procedure is then repeated 3 to 6 times at 6-week intervals until substantial elevation has been achieved. This can be followed by a more superficial resurfacing procedure such as medium-depth peeling, laser resurfacing, or dermabrasion to smooth the more superficial scars and blend them with other treated areas.

The physician must warn the patient about potential dyschromia, especially in Fitzpatrick skin types III through VI, as skin destruction of this depth can depigment the treated areas. The multiple procedures may not be able to raise all the scars to the surface but they will surely provide improvement. The TCA CROSS technique does add another simple therapeutic option for treating scars.

Deep Chemical Peeling

Patients in Glogau groups III and IV may require deep chemical peeling, motorized dermabrasion, or laser resurfacing to improve their greater degree of skin damage. Deep chemical peeling leads to production of new collagen and ground substance down to a level in proportion to the depth of the peel. Deep chemical peels create an injury through the papillary dermis and into the superficial reticular dermis, which may extend into the mid-reticular dermis. For deep peeling, either TCA in concentrations >50% or a phenol-containing preparation is used. Because of the risk of scarring and other complications with such potent concentrations of TCA, this agent is not recommended for deep chemical peeling. Therefore, solutions containing phenol remain the preferred formulation for deep chemical peels[40–46].

A deep chemical peel is one of the most permanent cutaneous rejuvenation procedures (Table 154.5)[46]. Histologically, it leads to a dense neocollagenesis zone with new elastic fibers that increases over 6 weeks (Fig. 154.11). The classic Baker–Gordon formula is outlined

Downloaded for Anonymous User (n/a) at Egyptian Knowledge Bank from ClinicalKey.com by Elsevier on March 10, 2024. For personal use only. No other uses without permission. Copyright ©2024. Elsevier Inc. All rights reserved.

DEEP PHENOL–CROTON OIL CHEMICAL PEELS	
• Phenol–croton oil formulas lead to deeper penetration than full-strength phenol* (see Table 154.6 for composition of Baker–Gordon formula) • Used for rejuvenation of severely photoaged skin (Glogau III and IV), with significant improvement or even elimination of deep furrows as well as other textural and pigmentary irregularities the expected result (Fig. 154.11)	
Potential specific complications and contraindications	
Cutaneous	• Scarring (Fig. 154.12), a "plastic" or alabaster appearance with an effacement of normal skin texture, hypopigmentation (greater problem in darker skin phototypes and men), persistent postoperative erythema for months
Systemic	• Cardiotoxicity
Contraindications	• History of cardiac arrhythmias or taking a medication known to precipitate arrhythmias
Relative contraindications	• History of hepatic or renal disease (phenol undergoes hepatic and renal elimination)
Preoperative evaluation and procedure	
Preoperative evaluation	• CBC, LFTs, BUN, crt, electrolytes, baseline electrocardiogram
Procedure	• Before administration of anesthesia (general or deep sedation), patient is examined while in a seated position and appropriate landmarks are noted • After thorough cleansing and degreasing of skin, chemical agent is applied sequentially to six aesthetic units: forehead, perioral region, right cheek, left cheek, nose, and periorbital region • The peel is extended slightly beyond the mandibular rim to conceal the demarcation between treated and untreated skin, but should not be extended to the vertical neck because of the risk of scarring in this area • Periorbital skin is treated cautiously and conservatively to avoid overpenetration, which can lead to ectropion or scarring; notably, diluting a phenol compound with water may increase its penetration so mineral oil (rather than water) should be used to flush the eyes if contact occurs • Cotton-tipped applicators are used; the technique is similar to that for a Jessner's–35% TCA peel (see text), but less solution is used because frosting occurs very rapidly • Following application, there is a burning sensation that lasts for 15–20 seconds, subsides for 20 minutes, and then returns for the next 6 to 8 hours • A 15-minute time interval between the treatment of each cosmetic area is recommended so the entire procedure requires 60 to 90 minutes
*Pure, undiluted 88% phenol is rarely used because it causes rapid and complete coagulation of epidermal keratin proteins and this blocks further penetration.	

Table 154.5 Deep phenol–croton oil chemical peels. BUN, blood urea nitrogen; CBC, complete blood count; crt, creatinine; IV, intravenous; LFTs, liver function tests; PAC, premature atrial contraction; PVC, premature ventricular contraction. Data from references 40–46.

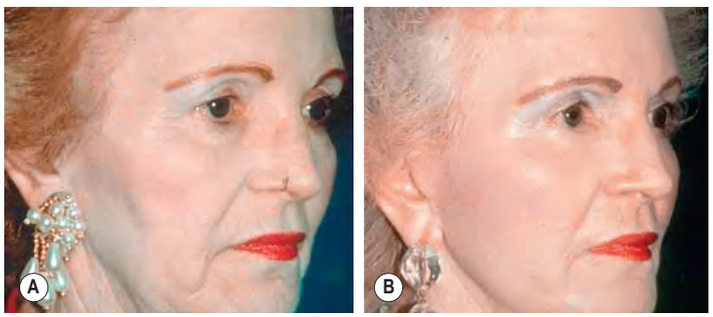

Fig. 154.11 Deep phenol–croton oil peel. A Before treatment. **B** 3 months after treatment with obvious reduction in rhytides.

THE BAKER–GORDON FORMULA		
Ingredient	**Amount**	**Comments**
88% liquid phenol, USP	3 ml	Final concentration of phenol is 50%–55%
Tap water	2 ml	Dilution increases penetration
Septisol® liquid soap (0.25% hexachlorophene)	8 drops	A surfactant that reduces skin tension, allowing more even penetration
Croton oil	3 drops*	A vesicant and epidermolytic agent that enhances phenol absorption Efficacy may be more related to the amount of croton oil than it is to that of phenol[40,42]
*Using 1 or 2 drops of croton oil, rather than the 3 in the Baker–Gordon formula, can limit the risk of phenol complications such as textural effacement or hypopigmentation.		

Table 154.6 The Baker–Gordon formula. The mixture or suspension of ingredients is freshly prepared and must be stirred vigorously prior to application due to its poor miscibility. USP, United States Pharmacopeia.

in Table 154.6. While it was originally thought that phenol was the active agent, in 1996 Hetter proposed, based upon careful data and animal studies, that croton oil was the active agent[40]. Others have subsequently confirmed the correlation of croton oil concentration with depth of wounding and there are various formulas of the Hetter peel (Table 154.7). While the expanded range of phenol–croton oil peels has increased their clinical applications and safety, performance of deep chemical peels requires experience.

The deep peel is indicated for moderate to severe photodamage (Glogau IV) and extensive rhytides in patients with skin types I–III. Associated lightening is an unwanted side effect in darker skin phototypes. Care must be taken in choosing the appropriate patient given the prolonged recovery and need for close monitoring to ensure proper healing. In addition, sedation and pain control, including the use of opioids, nonsteroidal anti-inflammatory drugs (NSAIDs) and benzodiazepines, are required during and after the procedure. A dull to moderately severe discomfort begins during the procedure and extends for up to 4 hours afterwards.

The peel solution should be freshly mixed and it separates easily without agitation. The face is divided into 6 cosmetic units and application time for each unit is 20 minutes such that the duration of a full-face treatment is 1½ to 2 hours. Because absorption occurs, this time spacing is required to limit serum phenol concentrations as it has both cardiac and renal toxicities. Intravenous hydration is administered prior to and during the procedure to assist in reducing phenol levels and the patient is monitored for cardiac arrhythmias.

After thorough cleansing with a detergent and acetone, the phenol–croton oil peel solution is applied with cotton-tip applicators, utilizing the correct number of passes and pressure to produce a visible solid white frosting. The latter appears very quickly after application and gradually resolves into a gray color with edema within an hour. While tape occlusion is the classic approach for creating deeper penetration, a lighter version is the *untaped* phenol–croton oil peel which heals faster and lessens the risk of overpenetration and scarring (Fig. 154.12). For the following 2 to 3 weeks, mild debriding soaks and ointments are

Downloaded for Anonymous User (n/a) at Egyptian Knowledge Bank from ClinicalKey.com by Elsevier on March 10, 2024. For personal use only. No other uses without permission. Copyright ©2024. Elsevier Inc. All rights reserved.

HETTER CHEMICAL PEELS WITH VARYING CONCENTRATIONS OF PHENOL AND CROTON OIL			
Type of peel	**Phenol (%)**	**Croton oil (%)**	**Cosmetic unit/indication**
Light	2.5	0.1	Eyelids, neck
Medium-depth	33	0.7	Cheeks, nose, chin; *not* for eyelids
Deep	33	1.1	Full-face except eyelids
Very deep (Baker–Gordon formula)	50	2.1	Lip rhagades, severe photo-damage with pale skin

Table 154.7 Hetter chemical peels with varying concentrations of phenol and croton oil.

Fig. 154.12 Complications from a Baker–Gordon phenol peel. There was prolonged non-healing, resulting in hypopigmentation and marbled scarring.

regularly applied. Prolonged postoperative care is required, along with medical supervision to assess for healing and early signs of potential complications (see below). Post-peel erythema may last as long as 6 weeks while collagen rejuvenation is occurring.

MECHANICAL RESURFACING PROCEDURES

For over 50 years, dermabrasion utilizing a rotating abrasive surface attached to a power-driven hand engine was considered the premier skin resurfacing procedure for facial scars. It has generally been regarded as a deep resurfacing modality based on its depth of injury and its prolonged healing time. The original descriptions of modern dermabrasion involved the use of a wire brush (which remains in use today), but there has been a movement toward more superficial methods of mechanical resurfacing. In 1957, the diamond fraise was introduced and became the preferred instrument for dermabrasion by some surgeons because it is less aggressive and more forgiving than the wire brush[47]. There has also been a resurgence of interest in manual dermasanding, which allows for more deliberate and controlled skin planing[4,5]. Microdermabrasion and microneedling are the mechanical resurfacing procedures developed most recently and represent the most conservative forms of mechanical resurfacing[3].

Microdermabrasion

Because microdermabrasion removes the stratum corneum and superficial spinous layer and the injury rarely extends past the basal layer, this modality is considered superficial in depth. Whether it is classified as very light or light in comparison to other superficial resurfacing procedures depends upon the technique and aggressiveness of the operator. The microdermabrasion unit's handpiece is a closed system, which propels aluminum oxide crystals at the skin at high speeds and simultaneously removes them with suction. These units were developed commercially in the mid-1990s and are currently in widespread use in both physicians' offices and non-medical aesthetic spas. Variants of this superficial resurfacing modality include hydrafacials and DermaSweep™ (DermaSweep, Inc.).

ADVANTAGES OF MANUAL DERMASANDING OVER MOTORIZED DERMABRASION
• Greater control over depth of injury, particularly on the lips and orbital rims • Blending of abraded areas into adjacent unabraded areas accomplished more easily and with better results • Lower cost and greater simplicity of instrumentation and set-up • Risk of aerosolizing infectious particles is far less • Possibly lower incidence of postinflammatory hypopigmentation

Table 154.8 Advantages of manual dermasanding over motorized dermabrasion.

Microdermabrasion may be indicated for acneiform conditions, pigmentary dyschromias, and as a "lunchtime" procedure for facial rejuvenation in all skin types[48], but in general it is not considered effective for improving the appearance of rhytides[49,50]. Both the patient and physician must understand that the degree of objective improvement with microdermabrasion may be limited. It is best used in conjunction with a regimen of topical "cosmeceuticals" including a retinoid, a bleaching agent, antioxidants and sunscreen, with the repeated superficial exfoliation of microdermabrasion enhancing the overall efficacy of the therapeutic program.

Ideal candidates for microdermabrasion typically desire facial rejuvenation without downtime. Appropriately selected patients have a subjective perception of improvement usually exceeding the objective signs depicted with photographs. Patients often report that their skin has a smoother texture and that cosmetics are easier to apply and they blend in with their skin more easily. Microdermabrasion has also been successfully combined with intense pulsed light (IPL) therapy to enhance penetration of the light.

Although the role of microdermabrasion in facial rejuvenation grew dramatically after its initial development, the scientific data to justify its use were lacking until more recently. An increase in epidermal and dermal thickness, flattening of the rete pegs, papillary dermal hyalinization, and newly deposited collagen and elastic fibers have all been observed[51]. Following microdermabrasion, there also appears to be a significant alteration in epidermal barrier function[52]. In addition, investigators have observed an elevation of transcription factors, cytokines, and matrix metalloproteinases following microdermabrasion[53]. This can lead to an enhancement of the effectiveness of topical agents. Microdermabrasion can also be used in combination with very light chemical peels (e.g. DermaSweep™).

Manual Dermasanding

Manual dermasanding involves abrading the skin by hand using silicon carbide sandpaper or wallscreen that is commercially available at any hardware store. It is gaining in popularity for skin resurfacing because it has several advantages over power-driven dermabrasion (Table 154.8). Its classification as a wounding agent is entirely dependent upon the type of paper used, the force applied by the surgeon, and the duration of contact with the skin. Although manual dermasanding can be used to produce a wound as deep as with wire-brush dermabrasion or several passes with a pulsed CO_2 laser, it is probably most commonly used as a medium-depth or "minimally deep" resurfacing modality.

Manual dermasanding can be used to resurface an entire face, but because it is so labor-intensive it is most often utilized for resurfacing localized regions to minimize the appearance of a scar[54] or to blend or enhance the effects of a medium-depth chemical peel or a combination procedure[55]. It can be used following a fractional laser resurfacing to feather the transition into hair-bearing areas that are inaccessible to the laser. Manual dermasanding of the eyebrows and hairline and gently abrading the upper neck at the inferior aspect of the laser-irradiated zone are all effective at minimizing lines of demarcation between treated and untreated skin (Fig. 154.13). It can also be useful immediately after laser resurfacing for stubborn rhytides, particularly in the perioral region; manual dermasanding can improve the outcome by producing a slightly greater depth of injury in a controlled fashion where further thermal injury would be risky. It will also remove adherent necrotic debris and thermal damage after laser resurfacing, thus enhancing the healing process. Similarly, a medium-depth chemical peel can be immediately followed by manual dermasanding of the more troublesome areas to enhance results as well as along the borders of the peeled skin to blend the effects.

Downloaded for Anonymous User (n/a) at Egyptian Knowledge Bank from ClinicalKey.com by Elsevier on March 10, 2024. For personal use only. No other uses without permission. Copyright ©2024. Elsevier Inc. All rights reserved.

Fig. 154.13 Dermasanding. Manual dermasanding utilizing G-320 grit silicon carbide sandpaper to blend CO_2 laser resurfacing into the eyebrow area. The sterilized sandpaper has been wrapped around rolled-up gauze pads and moistened with saline or soap-free cleanser for lubrication.

Our clinical experience suggests that dermasanding after a Jessner's–35% TCA peel may yield impressive postoperative results that approach those seen with either motorized dermabrasion or fractional CO_2 laser resurfacing in patients with cutaneous photoaging (Fig. 154.14). This combination is particularly helpful in patients who may not tolerate the greater degree of sedation often necessary with CO_2 laser resurfacing or who cannot afford the additional fees to cover anesthesia services.

The necessary materials for manual dermasanding include silicon carbide sandpaper or wallscreen. Both may be purchased in a variety of grades: fine grade (G-400), medium grade (G-220–320), and coarse grade (G-180). The sandpaper is easier to use because of its flexibility; it is also more easily cut into smaller pieces, which can be steam autoclaved. A 1.5-inch (4 cm) × 3-inch (8 cm) piece of sterilized sandpaper is wrapped around either the barrel of a 3 ml syringe or a rolled-up gauze pad and moistened with saline or a soap-free cleanser for lubrication. A 1% solution of lidocaine with epinephrine (adrenaline) may be used if additional anesthesia is necessary. The skin is stretched and both back-and-forth and circular motions are used to gradually abrade the skin, layer by layer, until the hills and valleys are softened or adjacent areas are blended to the desired degree. Coarser grades (G-320) may be used initially for "debulking", followed by finer grades (G-400) later in the procedure. The fine grade is used to blend delicate areas of skin such as around the eyelids. At the completion of the procedure, the dark-colored silicon carbide particles remaining on the skin surface should be rinsed off because there is a risk of their becoming implanted, creating a pigmented tattoo.

Motorized Dermabrasion

Although various abrasive materials have long been used for mechanical resurfacing, the development of a power-driven unit to facilitate the procedure was revolutionary. Some of the units most commonly used today are the Bell Handengine (Bell Handengine®, Inc.), the AEV-12 hand engine (Ellis International), and the Osada surgical handpiece (Osada, Inc.). A topical refrigerant spray was routinely used to produce anesthesia and to harden the skin as it is abraded (Fig. 154.15). The spray immobilizes the topographic features so that there is no distortion by the pressure of the abrasive instrument. Concerns regarding potential harm to the environment from cryogenic sprays have limited the availability of topical refrigerant sprays in several countries, including the US. Utilizing liquid nitrogen or agents that cryopreserve tissue specimens is *not* recommended because they create a colder temperature that can lead to hypopigmentation and/or scarring. Options include tumescent anesthesia as a means of firming the tissue or use of the diamond fraise without a cryogen.

The two abrasive instruments most often employed with these motor-driven units are the wire brush and the diamond fraise. The wire brush has numerous small-caliber, stainless steel wires that project circumferentially from the curved side of a cylindrical hub. A diamond fraise consists of a stainless-steel cylinder to which industrial-grade diamonds are bonded to create the abrasive surface. Compared with wire-brush instruments, diamond fraises are manufactured with a greater variety in their shape, width of abrasive surface, wheel diameter, and coarseness

Fig. 154.14 Medium-depth chemical peel plus manual dermasanding. Jessner's–35% trichloroacetic acid was applied to the face followed immediately by manual dermasanding of the cutaneous lips and chin. **A** Preoperative with obvious perioral rhytides. **B** Postoperative with significant improvement.

Fig. 154.15 Mechanical dermabrasion. This technique is performed with a diamond fraise over rigid skin cooled with a topical refrigerant spray. More recently, the latter has been replaced by tumescent anesthesia.

Downloaded for Anonymous User (n/a) at Egyptian Knowledge Bank from ClinicalKey.com by Elsevier on March 10, 2024. For personal use only. No other uses without permission. Copyright ©2024. Elsevier Inc. All rights reserved.

of grit. While there continues to be considerable controversy regarding which one of these instruments is superior[47], surgeons generally agree that the wire brush is more aggressive. The wire brush cuts more quickly and more deeply into the skin with each stroke, thereby posing a greater risk for injury and requiring more skill to operate. Although the diamond fraise is generally safer and more forgiving, it may not yield the degree of improvement possible with the wire brush, especially for more stubborn conditions such as acne scarring.

Because dermabrasion with either instrument is highly technique-dependent and the learning curve is steep, there may be considerable variability in the clinical results obtained by different operators. To be adequately trained, it is very important for beginner dermabraders to receive hands-on instruction from an experienced operator. The proper techniques for motorized dermabrasion have also been the subject of comprehensive reviews in the literature[47]. Careful evaluation of the depth of injury throughout the procedure is critical to assure a sufficient depth for optimal results without penetrating beyond the desired level and risking scar formation. Because of the potential for aerosolization of infectious particles during dermabrasion, appropriate precautions are mandatory to protect the operating room staff (see Ch. 136). This includes protective masks, face shields, and an air evacuation system.

Although the resurgence of manual dermasanding and the development of laser technology have led to a decline in the number of motorized dermabrasion procedures, it remains a reliable treatment for moderate-to-severe acne scarring (Fig. 154.16). Dermabrasion selectively planes off the "hilltops" that surround the atrophic "valleys", whereas chemical peeling and laser resurfacing may produce an injury of equivalent depth in both areas. This explains that while it is possible to efface the edges of atrophic scars with the CO_2 laser or the solid CO_2–35% TCA peel[31], it may prove more difficult to achieve desired results (compared to dermabrasion).

The physician must choose the scars most amenable to dermabrasion alone. These include shallow fibrotic scars, hypertrophic scars and undulating, rolling scars, in addition to atrophic and boxcar scars. Deeper fibrotic scars, ice-pick scars, and scars with significant tissue loss may require a lifting or filling procedure prior to dermabrasion. In these patients, the results are significantly enhanced by performing one or more of the following adjunctive procedures 4 to 6 weeks preoperatively: punch or scalpel excision, TCA CROSS technique, punch grafting, dermal grafting, fat grafting, or scar undermining (subcision)[56].

Subcision

Deeper fibrotic scars can be excised or they can be elevated prior to resurfacing[57]. Subcision represents a surgical option for elevating scars in which the scars are outlined, photographed, cleansed, and injected with local anesthesia. A specialized undermining needle (e.g. Nokor™) or a tri-beveled 18-gauge needle is inserted at an acute angle through an incision at the edge of the scar (Fig. 154.17). The needle is then advanced under the scar, horizontally and parallel to the skin surface. Fan-like motions break fibrotic dermal scar bands, releasing the overlying skin to raise upward. A pressure dressing is placed to evacuate blood from the pocket that is created under the scar. During wound healing, this pocket fills with new collagen fibers leading to scar elevation[58]. The procedure is usually repeated 2 to 5 times. Sometimes to further enhance filling in of the scar, a dermal graft harvested from the retroauricular area can be inserted with jeweler's forceps into the pocket generated by the Nokor™ needle.

Microneedling

Microneedling represents a minimally invasive procedure in which the device contains multiple fine-gauge needles 0.5–3 mm in length that penetrate the skin and trigger wound healing. One goal is to induce dermal remodeling and skin rejuvenation via increased production of collagen and elastin[59,60]. The devices vary from manually operated to battery- or electric-powered and are designed as rollers, automated pens, and patches in which the operator can often toggle between different lengths of needles. Clinical indications include acne, surgical, traumatic and burn scars, photoaging, striae, skin laxity, dyschromias, alopecia, and potentially transdermal drug delivery (Table 154.9).

Preoperatively, a topical anesthetic may be applied and multiple sessions are frequently needed to obtain desired results. Transient erythema is the most common side effect and rarely hypersensitivity reactions, scar formation, or dyspigmentation occur. Advantages include relatively low cost, wide spectrum of applications, overall ease of use, and favorable side effect profile including its relative safety in skin of color[61]. However, there is a lack of high-quality, prospective, randomized controlled trials comparing microneedling with other resurfacing modalities.

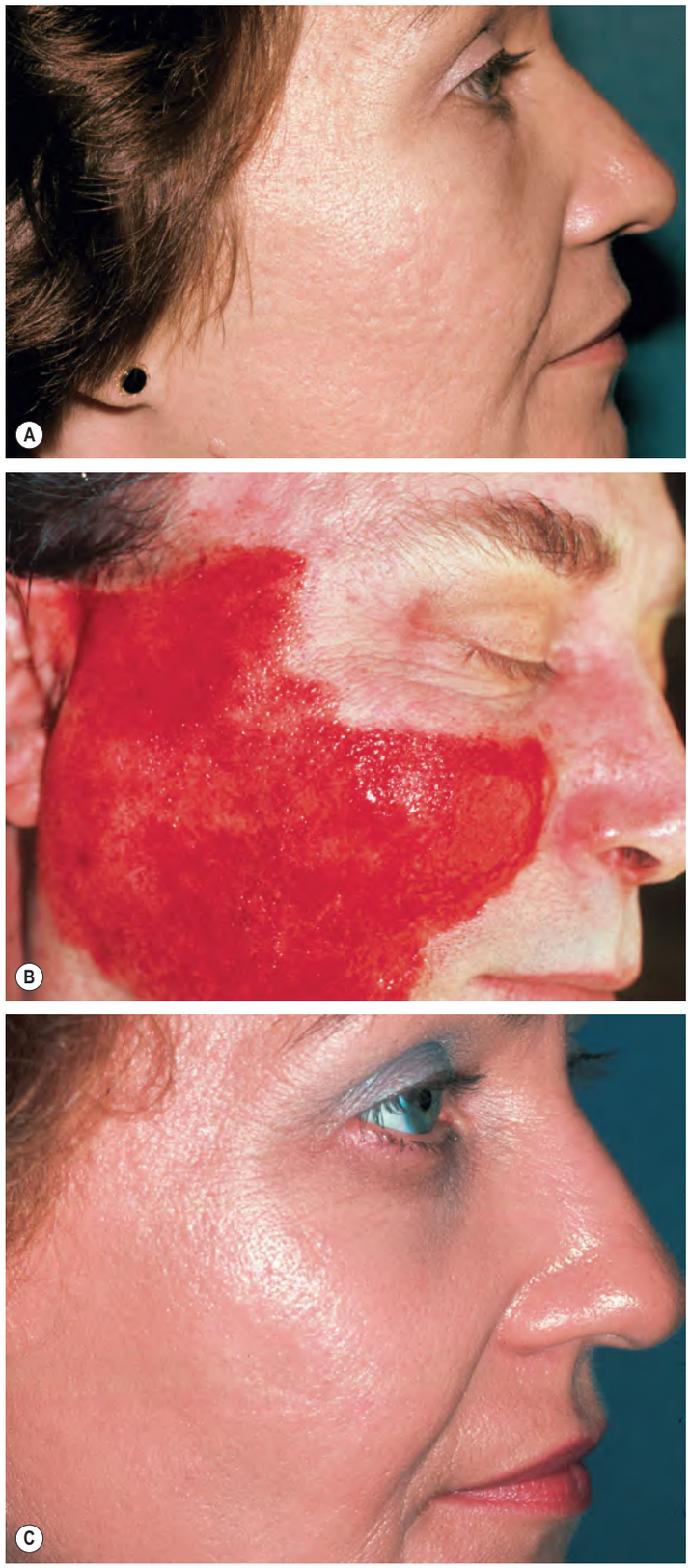

Fig. 154.16 Full-face dermabrasion performed for acne scars. A Preoperative: shallow and atrophic scars that are most amenable to dermabrasion. **B** Postoperative: dermabrasion prior to biosynthetic dressing. **C** Three months postoperative.

Downloaded for Anonymous User (n/a) at Egyptian Knowledge Bank from ClinicalKey.com by Elsevier on March 10, 2024. For personal use only. No other uses without permission. Copyright ©2024. Elsevier Inc. All rights reserved.

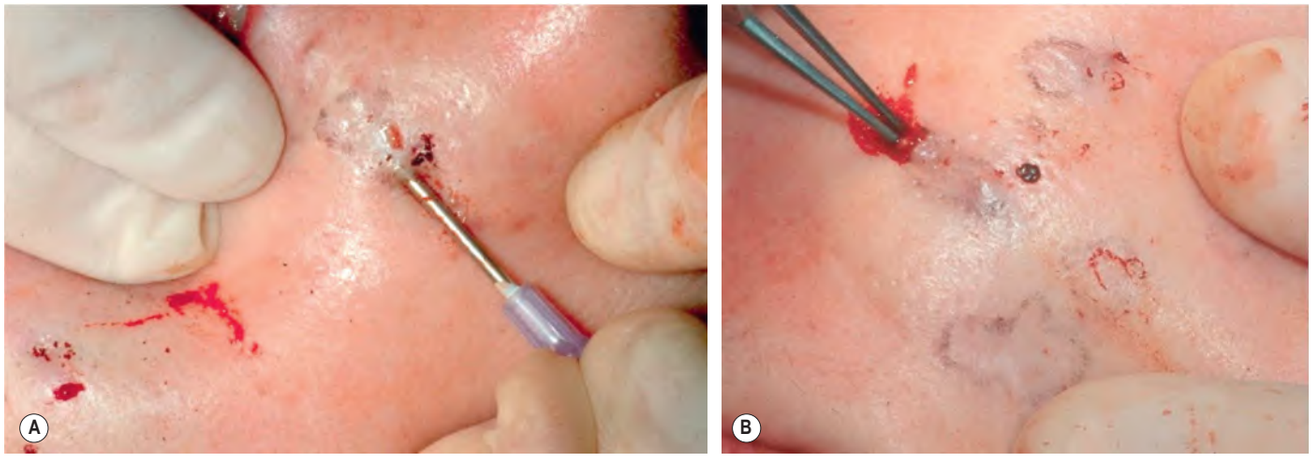

Fig. 154.17 Treatment of facial scars by subcision. A Scars to be treated have been outlined with a skin marker, photographed, and anesthetized. A Nokor™ needle is inserted into the dermis underneath a scar and advanced horizontally parallel to the skin surface. **B** To further enhance filling in of the scar, a dermal graft can be inserted with jeweler's forceps into the pocket generated by the Nokor™ needle.

EXAMPLES OF DRUGS DELIVERED TRANSDERMALLY VIA MICRONEEDLING	
Drug	**Treatment/indication(s)**
Anesthetics (topical)	Enhance anesthetic effect prior to minimally invasive procedures
Bimatoprost	Hypopigmentation
Bleomycin	Refractory verrucae vulgares
Botulinum toxin	Increased pore size, skin texture irregularities
Corticosteroids	Scars, bulky flaps
Cosmeceuticals	Melasma (transexamic acid), photoaging, skin texture irregularities
Platelet rich plasma (PRP)	Alopecia (e.g. androgenetic), photoaging

Table 154.9 Examples of drugs delivered transdermally via microneedling.

A promising variant is radiofrequency (RF) microneedling in which thermal-assisted microneedles stimulate new collagen formation by inflaming and destroying the dermis or subcutaneous tissue. Because the energy source is an electric current and the energy is not emitted until the dermal–epidermal junction is breached, there is minimal risk of hyperpigmentation[62]. Indications are those of traditional microneedling and cellulite improvement. See Chapter 137 and Table 137.1 for additional details.

POSTOPERATIVE CARE

Because superficial resurfacing procedures generally do not extend beyond the epidermis, the dermal wound healing mechanisms are not activated. In contrast, medium-depth and deep resurfacing procedures stimulate the following four stages of dermal wound healing (see Ch. 141): (1) inflammation and coagulation; (2) re-epithelialization; (3) fibroplasia and matrix formation; and (4) collagen remodeling.

Because the pronounced edema following medium-depth and deep resurfacing procedures may minimize the appearance of scars, rhytides and other irregularities, the patient's initial perception of his or her improvement may be exaggerated. As swelling subsides postoperatively, patients should be reassured and advised that collagen remodeling continues for several months and leads to further clinical improvement. At some point in the postoperative course, patients often want to know when another resurfacing procedure can be performed if it is necessary. The presence of persistent postoperative erythema may indicate continued collagen remodeling and may serve as a warning that a similar resurfacing procedure performed prematurely could produce scarring. To assure their safety, patients undergoing medium-depth resurfacing should not undergo another medium-depth or deep procedure for the next 3 to 9 months. An individual having a deep resurfacing procedure should avoid another one for at least 12 months postoperatively. Touch-up procedures for revision of a prior suboptimal outcome are also best avoided during these time periods, especially if erythema is still present.

Healing time is generally proportional to the depth of the resurfacing procedure. *Superficial* resurfacing procedures cause minimal downtime and necessitate little postoperative care. They usually produce mild erythema and desquamation that last from 1 to 4 days depending on the wounding agent and the techniques used. Regular washing with a mild cleanser and the use of routine moisturizers and sunscreens are generally sufficient during the healing period.

Following *medium-depth* resurfacing procedures, there is a considerably longer healing time and more intensive postoperative care is necessary. Follow-up visits are scheduled regularly to monitor the patient's postoperative course. After a medium-depth chemical peel, occlusive dressings are not necessary because the epidermis, which is not removed intraoperatively, functions as a biologic dressing until peeling occurs. Because areas of medium-depth peeling which have been enhanced by manual dermasanding do not possess residual epidermis, occlusive dressings may be used on these areas during the first 3 postoperative days.

The patient is instructed to soak the areas four times daily with warm compresses and to apply an emollient after each soak and during the intervening periods as necessary. A solution of 0.25% acetic acid (one tablespoon of white vinegar added to one pint of warm water) is preferred for the soaks because the mild acidity is physiologic for healing granulation tissue. It is also a mild debridant and has antibacterial effects, especially against *Pseudomonas* spp. and other Gram-negative organisms. Occlusive emollients, such as petrolatum, Aquaphor® or Eucerin® ointment, speed the process of re-epithelialization and lessen the tendency for delayed healing[63]. These emollients are also helpful in wound debridement and in the prevention of crust formation and infection. Showers, soaks, and emollients are continued for a week postoperatively.

Following medium-depth resurfacing, edema begins to appear almost immediately and progressively worsens during the first 48 hours. It can even be severe enough to close the eyelids and impair the patient's visual fields. If tolerated, aspirin or other NSAIDs can be administered, preoperatively and during the first 24 hours postoperatively, to alleviate discomfort and reduce swelling. After a medium-depth chemical peel such as the Jessner's–35% TCA peel, there is initially a brawny, dusky erythema which is followed by the formation of a brownish crust that begins to separate from the skin surface between days 4 and 8 postoperatively. Although the initial darkening can be disturbing to the patient, it represents an expected separation of the epidermis. The underlying, newly formed epithelium is brightly erythematous but fades to a pink color that resembles a sunburn (see Fig. 154.6D). By postoperative day 7 to 10, re-epithelialization has occurred and the erythema can be camouflaged with cosmetics. Within 2 to 4 weeks after the procedure, the erythema usually resolves fully, and retinoids and sunscreens can be restarted as tolerated.

Deep resurfacing procedures, such as the Baker–Gordon phenol peel or dermabrasion, require a follow-up visit the next day, several visits during the first week, and very close monitoring thereafter. At each visit, instructions for wound care are reviewed with the patient

Downloaded for Anonymous User (n/a) at Egyptian Knowledge Bank from ClinicalKey.com by Elsevier on March 10, 2024. For personal use only. No other uses without permission. Copyright ©2024. Elsevier Inc. All rights reserved.

and any questions are answered. The immediate postoperative course after deep resurfacing is similar to that following medium-depth procedures, except that edema and erythema may be even more severe and persistent. NSAIDs can provide some relief, but an intramuscular corticosteroid injection is often administered on the day of surgery, even though its effects on wound healing are not completely understood. Pruritus may occur during the healing phase following a resurfacing procedure of any depth but is particularly prevalent after deeper resurfacing. This problem can be alleviated by the use of emollients, ice packs, NSAIDs, and antihistamines until the pruritus spontaneously resolves. Milia formation, which commonly occurs 3 to 4 weeks after deep chemical peeling or mechanical resurfacing, is easily managed with needle extraction.

Patients undergoing deep mechanical resurfacing with either motorized dermabrasion or manual dermasanding can have an occlusive hydrogel biosynthetic dressing (e.g. Vigilon®, 2nd Skin®) applied immediately after the procedure. In patients undergoing a Baker–Gordon phenol peel, occlusive tape or a biosynthetic dressing is usually utilized postoperatively. Occlusive tape dressings must be removed on the first postoperative day and this procedure may require analgesia and sedation. For this reason, the authors prefer untaped phenol peels with application of ointment or bio-occlusive dressings. Whenever a biosynthetic dressing is used, it must be removed daily and replaced with a new one for the first 2 or 3 days postoperatively so that the face can be gently debrided with saline soaks and moistened cotton tips. The patient should be instructed to regularly apply an occlusive ointment to areas around the mouth, eyelids, and hairline that are not adequately covered by the dressing. Occlusive biosynthetic dressings have been shown to enhance collagen synthesis and hasten re-epithelialization in superficial wounds. They also minimize the amount of discomfort and obviate the need for repeated soaks by the patient during the first few days after the procedure.

By the third day following deep mechanical or chemical resurfacing, the patient begins open wound care with 0.25% acetic acid soaks four to six times daily and regular applications of an occlusive ointment. By the 7th to the 14th day postoperatively, re-epithelialization is usually complete and the ointment is replaced by a heavy moisturizer. The marked edema and erythema typically seen after dermabrasion or dermasanding generally resolve after several weeks. The erythema resulting from deep peeling may be more persistent but is rarely present beyond 2 to 4 months. Strict sun avoidance is critical for 3 to 6 months after dermabrasion or deep chemical peeling. The patient typically restarts sunscreens and retinoid therapy within a couple of weeks of re-epithelialization, as tolerated.

COMPLICATIONS

Complications may occur following any method of skin resurfacing involving injury to any depth but are more common after medium-depth and deep procedures. It is far simpler to prevent the development of a complication than to manage it once it has occurred. Complications may be prevented by proper selection of suitable patients and appropriate resurfacing modalities, precise intraoperative technique, and proper patient management before and after the procedure (see Table 154.3). The dissatisfied patient represents a complication even when the cosmetic result is favorable. An explanation of realistic results and review of photographs of "average" rather than best results during the pre-treatment consultation is recommended. Any information provided at this time is included within informed consent.

Improper wound care, trauma to healing areas resulting from overzealous debridement, compulsive picking or scratching, and premature use of irritating substances such as depilatories or wax for the removal of hair can each cause the depth of injury to extend beyond the threshold of safety. As discussed below, the development of infection in the postoperative period can also extend the depth of injury and increase the risk of permanent sequelae.

With specific regard to chemical peeling, excessive injury to the skin can result from poor technique during application or problems with the chemical agents utilized. The degree of frosting is monitored closely to assure that the agent has been applied evenly and that the injury extends to the proper depth (Table 154.10). Although it does not always correlate completely with the depth of injury, the level of frosting is a very valuable guide for determining the appropriate endpoint of treatment

CLINICAL SIGNS THAT REFLECT DEPTH OF WOUNDING
• Level of frosting (see Fig. 154.3)
• Time for frosting to appear
• Time for frosting to disappear
• Skin turgor
• Epidermal slide*
*Sliding of the epidermis off the dermis due to separation of the two tissues.

Table 154.10 Clinical signs that reflect depth of wounding.

(see Fig. 154.3). Injuring the skin too deeply during a chemical peel, as suggested by an excessive degree of frosting, may result not only from over-application but also from the use of excessively concentrated peeling solutions. The latter error can be caused by the surgeon's choice of an improper peeling agent, such as 50% TCA, or it can be related to unexpected disturbances in a solution's pharmacologic mixture. For Baker–Gordon peels, a new batch should be mixed by the surgeon prior to each procedure to be certain that the preparation is made correctly; the other peeling solutions are available in various formulations and strengths for purchase directly from medical supply dealers. Reputable dealers mix and label these solutions properly according to standard *weight-to-volume* formulas. It should be noted that the latter accurately reflect the TCA percentages cited in the medical literature, while volume-to-volume and weight-to-weight preparations of TCA do not.

Storage of peeling solutions in proper containers away from sunlight and immediate replacement of expired solutions are important measures to ensure chemical stability of the agents being used[64]. Immediately prior to peeling, an ample volume of the solution should be poured from the primary storage container into a smaller, secondary cup. The peeling agent is applied directly to the skin surface from this cup and the excess subsequently discarded to avoid contamination of the storage container and to avoid the accidental transfer of concentrated crystals from the neck of the storage container to the patient's skin.

Errors during mechanical resurfacing procedures may also lead to an injury of excessive depth and a higher risk of adverse sequelae. This problem can result from poor technique in the handling of the instruments or from failure to recognize the appropriate treatment endpoint. The beginner should first start by conservatively dermasanding small areas to get a comfortable feel for the skin's response to this type of injury. As knowledge and experience is gained, one can then progress on to diamond fraise dermabrasion and later to the use of the wire brush. Observation of experienced surgeons and hands-on training are invaluable. The beginner should always err on the side of conservatism, while still yielding favorable results, to avoid excessively deep tissue injury that could produce long-term complications.

During chemical peeling or mechanical resurfacing, intraoperative exposure of vital structures to the resurfacing agent may occur and can have serious adverse consequences. Extreme care must be exercised when dermabrading with a power-driven, rotating instrument, assuring that the dominant hand maintains complete control continuously and free skin edges (e.g. eyelid, lip) are not caught up in the wire brush or diamond fraise, as the latter may result in tearing of the skin. During chemical peeling, the moistened applicator should never be passed over the central face, in order to avoid inadvertent exposure of a vulnerable surface such as the eye to the solution. There should always be appropriate fluids readily available to rinse the area in case such an exposure does occur. In particular, saline is used to dilute TCA, mineral oil is used to dilute phenol solutions, and sodium bicarbonate is used to neutralize glycolic acid.

Adverse systemic effects related to a resurfacing procedure are very uncommon but can usually be traced to an identifiable causative factor in the perioperative period. Peeling with phenol solutions has been associated with systemic toxicities, so these procedures must be performed slowly and only on properly selected, healthy patients in an appropriate clinical setting. The use of Jessner's solution poses a theoretical risk of systemic salicylate or resorcinol toxicity, but this is probably not clinically significant when application is limited to the face and neck. Undoubtedly, the most common cause of systemic problems related to resurfacing procedures is an adverse allergic or physiologic reaction to a medication used for anesthesia. It is imperative that the surgeon knows all the physiologic effects and the potential adverse consequences of each drug administered systemically, unless there is an

Downloaded for Anonymous User (n/a) at Egyptian Knowledge Bank from ClinicalKey.com by Elsevier on March 10, 2024. For personal use only. No other uses without permission. Copyright ©2024. Elsevier Inc. All rights reserved.

attending anesthesiologist who assumes this responsibility. Fortunately, the chemical and mechanical resurfacing procedures utilized most often can be performed with little or no sedation.

It is important to make a distinction between a true complication and an expected side effect of a resurfacing procedure. With medium-depth and deep resurfacing, transient erythema, flushing, increased skin temperature, pruritus, edema, and milia formation are typical occurrences, so they should not be classified as true complications. Patient reassurance may be all that is necessary, since these problems usually resolve spontaneously. True complications that may develop within a treated area include infection, delayed wound healing, persistent erythema, scarring, and pigmentary or textural abnormalities[65,66]. Any of these true complications can occur despite proper patient and procedure selection, perfect surgical technique, and appropriate management before and after the operation.

Infection is an uncommon complication that develops during the postoperative period and may be caused by bacterial, viral, or fungal organisms. An important preventive measure is the repeated use of soaks for adequate wound debridement. Frequent postoperative visits are also helpful to assure early recognition and treatment of any infection so that scarring does not result. An infection may present with delayed wound healing, ulcerations, excessive necrotic material and crusting, purulent drainage, or odor. An acneiform eruption or pustular folliculitis can also be a manifestation of infection and should be treated as such. Infection with streptococcal and staphylococcal organisms can occur under biosynthetic membranes or thick, occlusive ointments, so these are best avoided, except in the immediate postoperative period. Other organisms, such as *Escherichia coli* or *Pseudomonas* spp., may infect the area if there is improper wound care. *Candida* infections can also occur and are sometimes related to the use of prophylactic antibiotics or occlusive wound care. Clinical suspicion of a wound infection necessitates immediate institution of empiric antimicrobial therapy, laboratory culture for identification of the organism(s), and wound debridement as necessary[67].

Herpes simplex viral infections can occur during the healing period following medium-depth or deep resurfacing and have the potential for devastating sequelae. An outbreak can even occur in patients on the recommended 10- to 14-day prophylactic antiviral regimen. The keys to avoiding scar formation are rapid recognition and aggressive therapy begun early in the course of the infection. The dosage of antiviral drug should be increased to the recommended maximum in cases of active herpetic infections.

Persistent erythema beyond 2 months after a medium-depth procedure may be precipitated by the use of topical or systemic retinoid therapy, contact with various allergens or irritants, an underlying skin condition, genetic susceptibility, or the presence of active infection[65,68]. Persistent erythema may indicate the impending development of scar formation. Especially when indurated, it should be treated promptly and aggressively. Management includes massage therapy, topical, intralesional or even systemic corticosteroids, silicone gel sheeting, and pulsed dye laser therapy. In most cases, scarring can be prevented. Mild scarring may even fade away spontaneously. Rarely, ectropion or eclabium can occur when aggressive resurfacing creates scarring or excessive tightening of periorbital or perioral skin, respectively, in a susceptible patient.

Textural abnormalities, skin atrophy, and dyspigmentation are additional complications that may occur with medium-depth and deep resurfacing procedures. The return of normal pigmentation in patients with Fitzpatrick skin type IV or higher is less predictable, so an extra measure of caution is necessary. Postoperative hyperpigmentation may be prevented and/or treated after re-epithelialization with a topical retinoid, a 4%–8% hydroquinone preparation, and strict photoprotection, but the hypopigmentation that can follow deeper resurfacing is typically permanent. Another potential pigmentary problem following deeper resurfacing procedures is a conspicuous demarcation line separating the untreated and treated areas. Although this problem can usually be avoided with adequate planning and proper technique, the approach to its management should focus on lightening the pigment in the adjacent untreated areas.

CONCLUSIONS AND FUTURE TRENDS

The sheer number of patients demanding medical therapy or procedural intervention to rejuvenate their skin mandates that dermatologists be well versed in this area. The field of resurfacing is constantly changing, with the development of new techniques and procedures as well as fluctuations in patient demands and expectations. In all areas of cosmetic surgery, there has been a recent trend in favor of less invasive procedures. Dermatologists often choose to learn and implement only a handful of resurfacing procedures that best fulfill the needs of their practice and meet the demands of their patient population.

Additional figures available in our eBook (see inside front cover for access code).

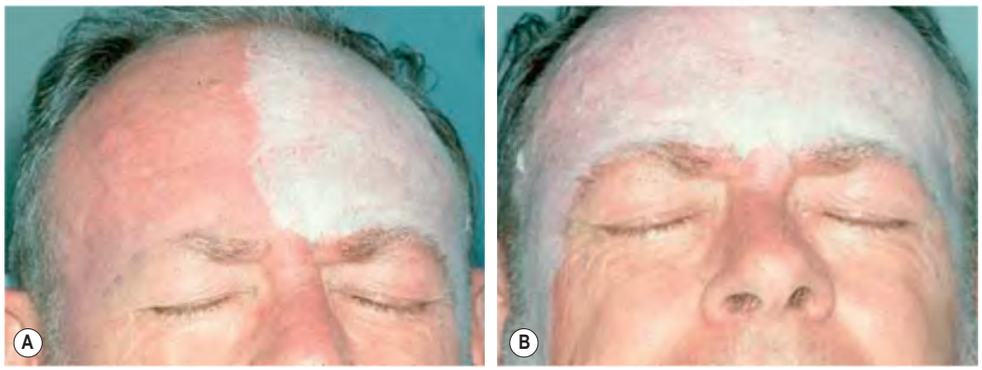

eFig. 154.1 Jessner's–35% trichloroacetic acid (TCA) chemical peel. A Patchy (level I) frosting following application of Jessner's solution. **B** After Jessner's solution dries, application of TCA leads to white enamel (level III) frosting.

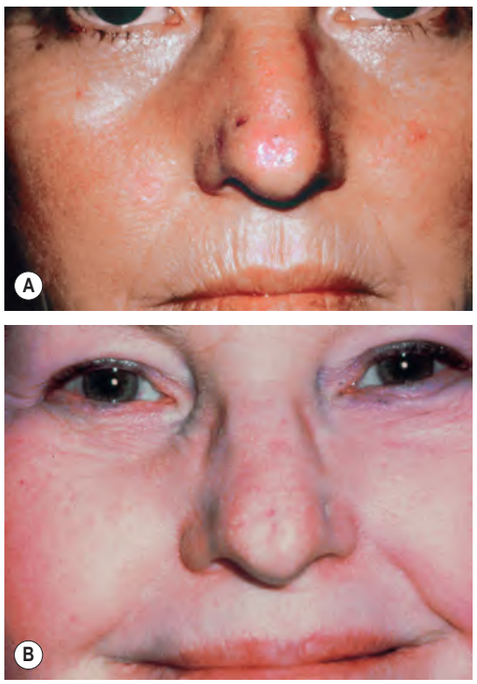

eFig. 154.2 Advanced photoaging in the form of perioral rhytides treated with a Baker–Gordon phenol peel. A Preoperative: perioral rhytides, textural and pigmentary changes, and keratoses. **B** Postoperative: 2 years later. Note the phenol peel maintains correction for many years.

eFig. 154.4 Scars to be treated by subcision are outlined with a skin marker and photographed. This serves as a guide for further treatment sessions.

eFig. 154.3 Microdermabrasion. Aluminum oxide crystals are propelled at high speeds within a closed system and removed with suction.

Downloaded for Anonymous User (n/a) at Egyptian Knowledge Bank from ClinicalKey.com by Elsevier on March 10, 2024. For personal use only. No other uses without permission. Copyright ©2024. Elsevier Inc. All rights reserved.

eFig. 154.5 Microneedling of the face in a 40-year-old woman with skin texture irregularities, melasma, and acne scarring. A, B Before treatment. **C, D** After three sessions of microneedling performed at 4- to 6-week intervals. No other light- or energy-based procedures, toxins, or soft tissue fillers were utilized during this period.

Downloaded for Anonymous User (n/a) at Egyptian Knowledge Bank from ClinicalKey.com by Elsevier on March 10, 2024. For personal use only. No other uses without permission. Copyright ©2024. Elsevier Inc. All rights reserved.